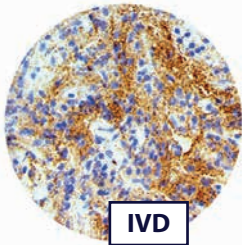


25 NOUVEAUX ANTICORPS



Formats prédilués : 3 ml, 7 ml et 15 ml

Formats concentrés : 0.1 ml, 0.5 ml et 1 ml

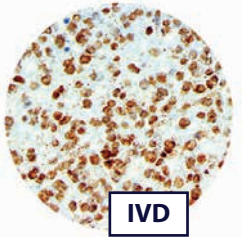


IVD

Alpha Synuclein, Clone MMab BSB-114

Alpha-synuclein pathology is also found in both sporadic and familial cases with Alzheimer's disease. In rare cases of familial forms of Parkinson's disease, there is a mutation in the gene coding for alpha-synuclein. Genomic duplication and triplication of the gene appear to be a rare cause of Parkinson's disease in other lineages, although more common than point mutations. Hence certain mutations of alpha-synuclein may cause it to form amyloid-like fibrils that contribute to Parkinson's disease.

Application: Neural and Neuroendocrine Cancer

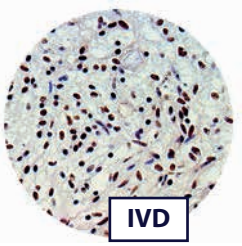


IVD

Amyloid Beta, Clone RMAb RBT-A4

Brain Amyloid beta is elevated in patients with sporadic Alzheimer's disease and is the main component of amyloid plaques. Similar plaques appear in some variants of Lewy body dementia and in inclusion body myositis, while Amyloid beta can also form the aggregates that coat cerebral blood vessels in cerebral amyloid angiopathy. The plaques are composed of a tangle of regularly ordered fibrillar aggregates called amyloid fibrils, a protein fold shared by other peptides such as the prions associated with protein misfolding diseases.

Application: Neural and Neuroendocrine Cancer

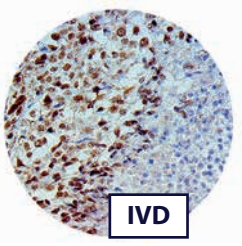


IVD

ATRX, Clone MMab BSB-108

ATRX is a protein that in humans is encoded by the ATRX gene. Mutation/loss of ATRX expression has been described in anaplastic gliomas. Survival analysis showed a marked separation of IDH mutant astrocytic tumors into two groups based on ATRX status: tumors with ATRX loss had a significantly better prognosis. Another study found ATRX immunoreactivity of tumor cells was either almost totally absent or completely retained in all cases. There was perfect concordance between the IHC results and ATRX mutation status. ATRX loss was observed in 54.5, 30.8 and 0.0% of grades II/III astrocytomas, oligoastrocytomas and oligodendrogliomas, respectively, and 12.7% of glioblastomas. Another recent study analyzed the use of ATRX, IDH and 1p/19q codeletion in a series astrocytomas, oligodendrogliomas, oligoastrocytomas and glioblastomas and presented an algorithm based on stepwise analysis with initial immunohistochemistry for ATRX and IDH1-R132H followed by 1p/19q analysis then by IDH sequencing, which reduces the number of molecular analyses and which has a far better association with patient outcome.

Application: Neural and Neuroendocrine Cancer

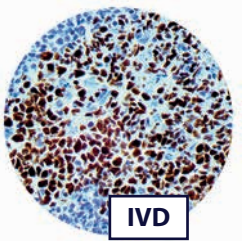


IVD

BAP1, Clone MMab BSB-109

BAP1 mutations have been identified in aggressive Mesotheliomas with similar mutations as seen in melanomas. Sequencing studies have been used to identify germline mutations in BAP1 in families with genetic predispositions to mesothelioma and melanocytic skin tumors. Mutations in the tumor suppressor gene BAP1 occur in approximately 15% of clear cell renal cell carcinoma cases. Sequencing reports demonstrated worse outcomes in patients with BAP1 mutated clear cell renal cell carcinoma. Immunohistochemistry for BAP1 is a prognostic biomarker to predict poor oncologic outcomes and adverse clinicopathological features in patients with non-metastatic clear cell renal cell carcinoma. BAP1 assessment using immunohistochemistry on needle biopsy may benefit preoperative risk stratification and guide treatment planning.

Application: Lung Cancer, Melanoma & Skin Cancer, Kidney & Urothelial Cancer

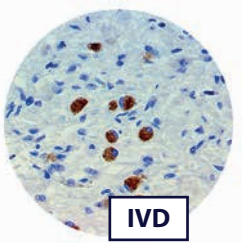


IVD

Bcl6, Clone MMab BSB-26

bcl-6 is a transcriptional regulator gene which codes for a 706-amino-acid nuclear zinc finger protein. Antibodies to this protein stain the germinal center cells in lymphoid follicles, follicular cells and interfollicular cells in Follicular Lymphoma, Diffuse Large B-Cell Lymphomas, Burkitt's Lymphoma, and the majority of the Reed-Sternberg cells in Nodular Lymphocyte-Predominant Hodgkin's Disease. bcl-6 is also useful in identifying neoplastic cells in cases of nodular Lymphocyte-Predominant Hodgkin's Disease. In contrast, anti-bcl-6 rarely stains Mantle-Cell Lymphoma and MALT Lymphoma. bcl-6 expression is seen in approximately 45% of CD30+ Anaplastic Large-Cell Lymphomas but is consistently absent in other peripheral T-cell Lymphomas.

Application: Hodgkin's and NHD Lymphoma, Lymphoma, Gall Bladder & Pancreatic Cancer



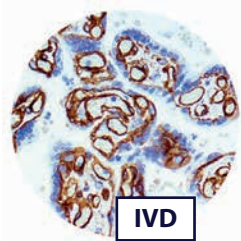
IVD

Brachyury, RPAb Polyclonal

Expression of the brachyury gene has been identified as a definitive diagnostic marker of chordoma, a malignant tumor that arises from remnant notochordal cells lodged in the vertebrae. Furthermore, germ line duplication of brachyury confers major susceptibility to chordoma. Brachyury is an important factor in promoting the epithelial-mesenchymal transition (EMT). Cells that over-express brachyury have down-regulated expression of the adhesion molecule E-cadherin, which allows them to undergo EMT. Overexpression of brachyury has been linked to Hepatocellular carcinoma. While brachyury is promoting EMT, it can also induce metastasis of HCC cells. Brachyury expression is a prognostic biomarker for HCC, and the gene may be a target for cancer treatments in the future. Additionally, overexpression of brachyury may play a part in EMT associated with benign disease such as renal fibrosis.

www.biosb.com | 1-805-692-2768 | info@biosb.com

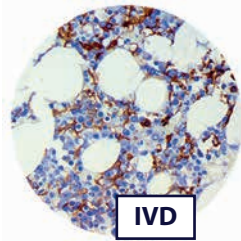
Application: Neural and Neuroendocrine Cancer, Liver Cancer



Caveolin 1, Clone RMAb EP353

CAV-1 is expressed at different levels in different tissues, with the highest in adipocytes, endothelial cells, fibroblasts, and mesothelial cells. CAV-1 is useful in assisting in the identification of epithelioid mesothelioma. Staining in most mesotheliomas has been reported as being strong and diffuse when compared with the weak, focal staining (no more than 1% of the tumor cells) seen in the lung adenocarcinomas and therefore CAV-1 is considered a very useful marker to help to differentiate these two malignancies. CAV-1 has been found to be comparable to other mesothelioma markers such as calretinin and podoplanin that are commonly used to assist in the differentiation between epithelioid mesotheliomas and lung adenocarcinomas. CAV-1 has also been found to be useful in the identification of Ewing sarcoma/PNET with expression in 96% cases of Ewing sarcoma/PNET. CAV-1 is also very useful in the differentiation of epithelioid mesothelioma from lung adenocarcinoma and identification of Ewing sarcoma/PNET.

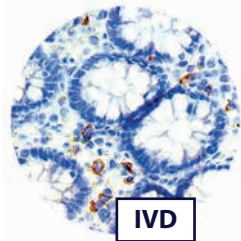
Application: Lung Cancer, Mesothelioma, Cytopathology



CD16, Clone RMAb EP364

The IHC of CD16 is useful in the differential diagnosis of hepatosplenic gamma delta T-cell lymphoma and gamma delta T-cell large granular lymphocyte leukemia from other peripheral T-cell lymphomas, such as mucosal and cutaneous gamma delta T-cell lymphoma. A significant decrease can be seen in the number of granulocytes expressing CD16 in chronic myelomonocytic leukemia compared to chronic myelogenous leukemia and control bone marrow biopsy, probably related to dysgranulopoiesis. It has also been demonstrated that colorectal carcinoma patients with high CD16+ cell infiltration is associated with improved overall survival after adjusting for known prognostic factors and this association was independent from CD8+ lymphocyte infiltration and presence of metastases.

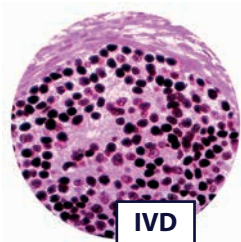
Application: Leukemia & Histiocytic, Lymphoma



CD33, Clone RMAb RBT-CD33

CD33 is a glycosylated transmembrane protein that is a member of the sialic acid-binding immunoglobulin-like lectin (siglec) family. The genomic locus of this protein has been mapped to chromosome 19q13.1-3.5. The function of CD33 is not known, but it may have a role in cell-to-cell adhesion. In maturing granulocytic cells, there is progressive down-regulation of CD33 from the blast stage to mature neutrophils. However, in monocytes and macrophages/histiocytes, strong expression of CD33 is maintained throughout maturation. Detection of CD33 using monoclonal antibodies has been a critical component in immunophenotyping acute leukemias, particularly Acute Myeloid Leukemias.

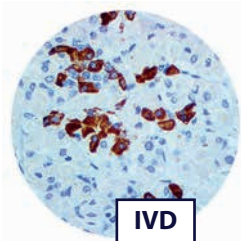
Application: Leukemia & Histiocytic, Sarcoma & Soft Tissue GATA3, RMAb (EP368)



GATA3, Clone RMAb EP368

GATA-3 is one of the three genes mutated in >10% of breast cancers. Nuclear expression of GATA-3 in breast cancer is considered a marker of luminal cancer in ER+ cancer and luminal androgen responsive cancer in ER-/AR+ tumors. It is highly coexpressed with FOXA1 and serves as negative predictor of basal subtype and HER-2 and is also considered a strong predictor of taxane and platinum salts insensitivity. GATA3 expression is found in urothelial carcinoma, especially in invasive and high grade tumors. Therefore, anti-GATA3 can be used in a panel of antibodies for diagnosis of unknown primary carcinoma, when carcinomas of the breast or bladder are a possibility. Studies have also shown the utility of GATA-3 in differentiating urothelial carcinoma from prostate adenocarcinoma and squamous cell carcinomas of the uterine, cervix, anus and lung.

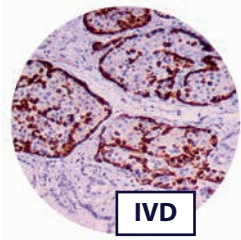
Application: Breast Cancer, Carcinomas of Unknown Primary Site



GH, Clone MAb BSB-99

Growth hormone (GH or somatotropin) is a 191 amino acid, single-chain polypeptide hormone which is synthesized, stored and secreted by the somatotroph cells within the lateral wings of the anterior pituitary gland, which stimulates growth and cell reproduction in humans and other animals. GH is a useful marker in classification of pituitary tumors and the study of pituitary disease (acromegaly). It reacts with Growth Hormone producing cells.

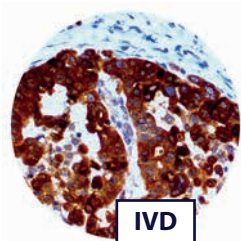
Application: Pituitary, Neural & Neuroendocrine Cancer



Glucagon, Clone MAb BSB-111

Glucagon antibody detects glucagon-secreting cells and tumors such as glucagonomas. Studies show that approximately 80% of glucagonomas are malignant and these patients have a syndrome most often initially recognized by dermatologists. Symptoms include necrolytic migratory erythema as well as diabetes, anemia, stomatitis, weight loss, frequent venous thromboses, and in some instances, diarrhea and psychiatric disturbances. The diagnosis may be readily confirmed by the demonstration of elevated plasma glucagon concentration.

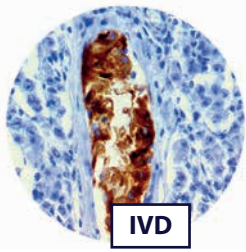
Application: Gall Bladder & Pancreatic Cancer, Neural & Neuroendocrine Cancer



HE4, Clone RMAb EP370

HE4 is a recognized biomarker in ovarian and endometrial cancer and over-expressed in pancreatic adenocarcinoma. In a series of 175 human adult tumors, gene expression was found to be the highest in ovarian serous carcinomas. However, adenocarcinomas of the lung, and occasional breast, transitional cell and pancreatic carcinomas had moderate or high levels of HE4 expression. IHC studies have shown that HE4 is significantly higher expressed in human pancreatic carcinoma tissues than in both normal and adjacent non-tumoral pancreatic tissues, and the staining intensity is inversely correlated with the clinical stage. HE4 is also highly expressed in early stage pancreatic adenocarcinoma.

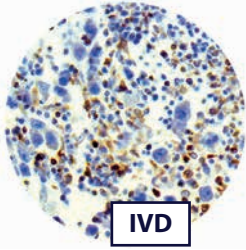
Application: Ovarian Cancer, Gall Bladder & Pancreatic Cancer, Lung Cancer



Inhibin Alpha, Clone RMAb EP378

Inhibins are peptide hormones produced by the granulosa cells in female follicles and by Sertoli cells in the male seminiferous tubules. They are selectively expressed by cells of sex-cord stromal derivation, and inhibit the secretion of follicle-stimulating hormone by the pituitary gland. Inhibin contains an alpha and beta subunit linked by disulfide bonds. Two forms of inhibin differ in their beta subunits (A or B), while their alpha subunits are identical. Inhibin belongs to the transforming growth factor-beta (TGF-beta) family. Anti-Inhibin Alpha has demonstrated utility in differentiation between Adrenal Cortical Tumors and Renal Cell Carcinoma. Sex-Cord Stromal Tumors of the Ovary as well as Trophoblastic Tumors also demonstrate cytoplasmic positivity with this antibody.

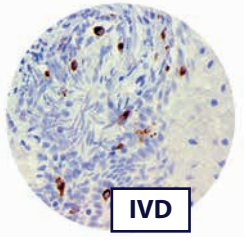
Application: Endometrial & Genital Cancer, Ovarian Cancer, Kidney & Urothelial Cancer



LAG-3, Clone RMAb EP294

LAG-3 is expressed on activated T cells, natural killer cells, B cells and plasmacytoid dendritic cells. The LAG-3 protein negatively regulates cellular proliferation, activation, and homeostasis of T cells, in a similar fashion to CTLA-4 and PD-1 and has been reported to play a role in Treg, regulatory T cells, suppressive function. LAG-3 also helps maintain CD8+ T cells in a tolerogenic state and, working with PD-1, helps maintain CD8 exhaustion during chronic viral infection. LAG-3 is known to be involved in the maturation and activation of dendritic cells. Studies have shown that LAG-3 is a prognostic indicator of poor treatment outcomes in chronic lymphocytic leukemia, has been associated with higher risk of multiple myeloma, may play a modulating role in autoimmune diabetes and has been identified in a subset of HIV-specific LAG-3(+) CD8(+) T cells that negatively correlated with plasma viral load. IHC studies have shown LAG-3 expression on lymphocytes scattered in renal cell carcinoma, melanoma and lymphomas.

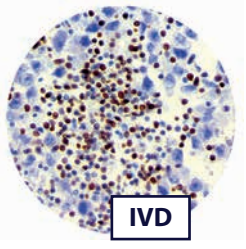
Application: Leukemia & Histiocytic, Rejection & Autoimmunity, Hodgkin's and NHL Lymphoma, Lymphoma, Immunotherapy



Langerin/CD2-7, Clone RMAb EP349

Langerin is a type II transmembrane cell surface receptor produced by Langerhans Cells, which are immature dendritic cells of the epidermis and mucosa. Epidermal LCs possess strong immunohistochemistry capacity and play a central role in the initiation and regulation of immune responses. Langerin is localized in the Birbeck granules, organelles present in the cytoplasm of Langerhans cells and consisting of superimposed and zippered membranes. It is a C-type lectin with mannose binding specificity, and it has been proposed that mannose binding by this protein leads to internalization of antigen into Birbeck granules and providing access to a nonclassical antigen-processing pathway. Human spleen, lymph node, thymus, liver, lung and heart express langerin protein. Langerin protein expression has utility in differentiating Langerhans cell histiocytosis from other non-Langerhans cell histiocytic proliferations.

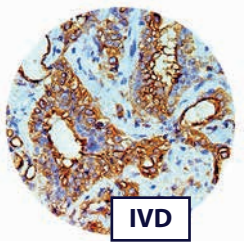
Application: Leukemia & Histiocytic, Sarcoma & Soft Tissues



LEF-1, Clone RMAb EP310

LEF1 is highly overexpressed and associated with disease progression and poor prognosis in B-cell chronic lymphocytic leukemia. Strong nuclear expression of LEF1 has been observed in majority of chronic lymphocytic leukemia/small lymphocytic lymphoma cases and LEF1 is not detected in other small B cell lymphomas. Gene expression profiling revealed overexpression of LEF-1 in chronic lymphocytic leukemia (CLL)/ small lymphocytic lymphoma (SLL). LEF-1 immunostaining has been detected in all neoplastic cells of CLL/SLL cases. LEF-1 was identified in 50% of high grade follicular lymphoma and 38% of diffuse large B-cell lymphoma, but not in mantle cell lymphoma or marginal zone lymphoma. Recently, high LEF-1 was demonstrated as a favorable prognostic marker in cytogenetically normal acute myeloid leukemia. Due to its high sensitivity, LEF-1 has been proposed to be a suitable immunohistochemical marker for diagnosis and differential diagnosis for CLL/ SLL. Alternatively spliced isoforms may play additional roles in regulating cell growth in colon carcinoma, and nuclear LEF-1 immunostaining was detected in 36% of adenocarcinoma brain metastases.

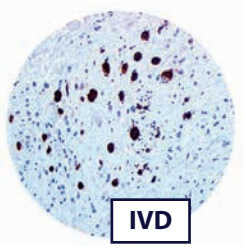
Application: Leukemia & Histiocytic, Lymphoma, Colon & GI Cancer, Brain Cancer



Mesothelial Cell, Clone MMab HBME-1

Mesothelial Cell HBME-1 has shown to label mesothelial cells, both benign and malignant (malignant mesothelioma) and thus has been used in distinguishing mesothelioma from adenocarcinomas of various origins. HBME-1 has also been used to distinguish Thyroid carcinomas (both Follicular and Papillary) from benign thyroid lesions. Mesothelial Cell HBME-1 and MOC-31 have been shown to have a diagnostic efficiency for the distinction between carcinoma and mesothelioma in pleura. HBME-1 staining may be useful for differentiating papillary carcinomas from follicular carcinomas; in papillary lesions it tends to be positive. The expression of HBME-1 and Galectin-3 in some thyroid nodules is related to the presence of cytological atypia suggestive but not diagnostic of PTC. The phenotypic similarity between this subset of thyroid nodules with cytological atypia and PTC is also confirmed by data according to which Galectin-3 and HBME-1 have been found to be highly sensitive for PTC.

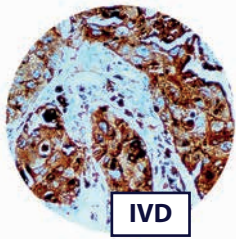
Application: Mesothelioma, Lung Cancer, Head & Neck Cancer, Gall Bladder & Pancreatic Cancer, Cytopathology



Myoglobin, Clone MMab BSB-104

Myoglobin is a single-chain globular protein of 153 amino acids, containing a heme (iron-containing porphyrin) prosthetic group in the center around which the remaining apoprotein folds. With a molecular weight of 16.7 kDa, it is the primary oxygen-carrying pigment of muscle tissues. Immunostaining with Myoglobin provides a specific, sensitive and practical procedure for the identification of Rhabdomyosarcoma. Since myoglobin is found exclusively in skeletal and cardiac muscle and is not present in any other cells of the human body, it may be used to distinguish Rhabdomyosarcoma from other soft-tissue tumors. Myoglobin staining is also useful when demonstrating rhabdomyoblastic differentiation in other tumors, e.g., Neurogenic Sarcomas and Malignant Mixed Mesodermal Tumors of the uterus and ovary.

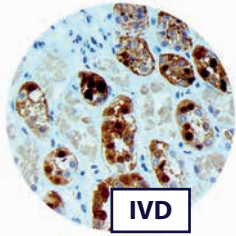
Application: Sarcoma & Soft Tissue



Napsin A, Clone MAb BSB-112

The activation peptides of aspartic proteinases play a role as inhibitors of the active site. These peptide segments, or pro-parts, are deemed important for correct folding, targeting, and control of the activation of aspartic proteinase zymogens. The pronapsin A gene is expressed predominantly in lung and kidney. Its translation product is predicted to be a fully functional glycosylated aspartic proteinase precursor containing an RGD motif and an additional 18 residues at its C-terminus. In normal tissue, anti-Napsin A labels type II pneumocytes in adult lung and epithelial cells in kidney tissues. In abnormal tissues, Napsin A is a useful marker for lung adenocarcinoma.


Application: Lung Cancer, Carcinoma of Unknown Primary Site, Cytopathology



Parvalbumin, Clone RMAb EP300

Parvalbumin is localized in fast-contracting muscles, where its levels are highest, as well as in the brain and some endocrine tissues. In normal kidney, parvalbumin has been shown to be limited to the distal tubular and collecting duct cells (the intercalated cells). Studies have demonstrated that parvalbumin may be a suitable IHC marker for distinguishing primary and metastatic chromophobe carcinoma from conventional (clear cell) and papillary renal cell carcinoma. Parvalbumin is strongly expressed in almost all primary, as well as metastatic, chromophobe renal cell carcinoma (RCC) (100%) and oncocytoma (69%), but is essentially negative in other types of RCCs, such as clear cell RCC and papillary RCC. Additionally, alterations in the function of parvalbumin-expressing neurons have been implicated in various areas of clinical interest such as Alzheimer's disease and age-related cognitive defects.

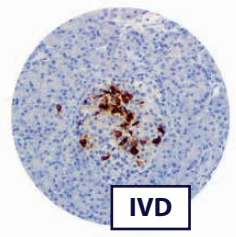
Application: Kidney & Urothelial Cancer



SMAD4/DPC4, Clone RMAb RBT-SMAD4

Approximately 55% of pancreatic cancers bear deletions or mutations in SMAD4/DPC4. Patients undergoing surgical resection of their pancreatic adenocarcinoma, survival of patients whose tumor expressed SMAD4 protein was significantly longer (unadjusted median survival, 19.2 months) as compared with 14.7 months without SMAD4 protein expression ($P = 0.03$). This SMAD4 survival benefit persisted after adjustment for prognostic factors including tumor size, margin status, lymph node status, pathological stage, blood loss, and use of adjuvant chemoradiotherapy. SMAD4 is also found mutated in the autosomal dominant disease juvenile polyposis syndrome (JPS). JPS is characterized by hamartomatous polyps in the gastrointestinal (GI) tract. These polyps are usually benign, however they are at greater risk of developing gastrointestinal cancers, in particular colon cancer.

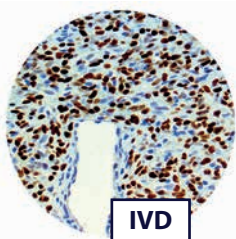
Application: Gall Bladder and Pancreatic Cancer, Liver Cancer, Colon & GI Cancer



Somatostatin, Clone MAb BSB-113

Somatostatin is secreted not only by cells of the hypothalamus but also by the stomach, intestine, and delta cells of the pancreas. It binds to somatostatin receptors. Somatostatin is a useful marker of D-cells of pancreatic islet cells. D-cells are used to identify hyperplasia of the pancreatic islets. Most of these tumors are malignant, giving rise to Somatostatinomas. Somatostatin suppresses gastric acid secretion, gallbladder contractions and pancreatic enzyme secretion.

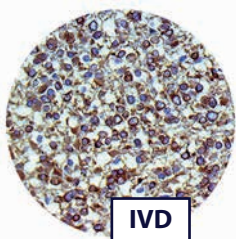
Application: Gall Bladder & Pancreatic Cancer, Neural & Neuroendocrine Cancer, Colon & GI Cancer



STAT6, Clone RMAb EP325

STAT6 is a human gene. The protein encoded by this gene is a member of the STAT family of transcription factors. It is found to induce the expression of BCL2L1/BCL-X(L), which is responsible for the anti-apoptotic activity of IL4. Recurrent somatic fusions of the NGFI-A-binding protein 2 (NAB2) gene and STAT6 gene have been identified in Solitary Fibrous Tumors (SFT). All other tumor types of soft tumor tissues were negative for STAT6, except for three differentiated Liposarcomas and one deep Fibrous Histiocytoma, which showed weak staining. STAT6 is a highly sensitive and specific immunohistochemical marker for SFT and can be helpful to distinguish this tumor type from histologic mimics. STAT6 is amplified in a subset of differentiated Liposarcoma, resulting in STAT6 protein expression that can be detected by immunohistochemistry and may be a potential pitfall in the differential diagnosis of differentiated Liposarcoma and Solitary Fibrous Tumor. These findings suggest a role for STAT6-mediated transcriptional activity in some cases of differentiated Liposarcoma and highlight the genomic complexity and heterogeneity of differentiated Liposarcomas.

Application: Sarcoma & Soft Tissues, Lung Cancer



Tau, Clone MAb BSB-115

The tau proteins are the product of alternative splicing from a single gene that in humans is designated MAPT (microtubule-associated protein tau) and is located on chromosome 17. Pathologies and dementias of the nervous system such as Alzheimer's disease and Parkinson's disease are associated with tau proteins that have become defective and no longer stabilize microtubules properly. Hyperphosphorylation of the tau protein (tau inclusions, pTau) can result in the self-assembly of tangles of paired helical filaments and straight filaments, which are involved in the pathogenesis of Alzheimer's disease, frontotemporal dementia, and other tauopathies. When misfolded, this otherwise very soluble protein can form extremely insoluble aggregates that contribute to a number of neurodegenerative diseases. Mutations that alter function and isoform expression of tau lead to hyperphosphorylation, which in turn disassembles microtubules and sequesters normal tau, MAP 1, MAP 2, and ubiquitin into neurofibrillary tangles, which are composed of paired helical filaments (PHF). These insoluble structures damage cytoplasmic functions and interfere with axonal transport, which can lead to cell death.

Application: Neural & Neuroendocrine